

The Use of Adipose-Derived Mesenchymal Stem Cells in the Treatment of Claw Lesions in Cows

Nataly Kostyuk¹, Andrei Prytychenka², Igor Volotovskiy³, Irina Vasilevich³, Sergey Pinchuk³, Vasili Rukal⁴, Roman Borisik⁴ and Aiken Karabassova⁵

¹Minsk, Republic of Belarus, Belarusian State University; ²Republican Subsidiary Unitary State Enterprise "Experimental Scientific Station for Poultry Breeding", Zaslavl, Republic of Belarus; ³SSI Institute of Biophysics and Cell Engineering NAS of Belarus, Minsk, Republic of Belarus; ⁴EI Vitebsk Order of the Badge of Honor State Academy of Veterinary Medicine, Vitebsk, Republic of Belarus; ⁵LLP Kazakh Scientific Research Veterinary Institute, Almaty, Republic of Kazakhstan

*Corresponding author's e-mail: prytychenka@mymail.academy

The treatment of claw lesions in cattle is one of the most pressing aspects of veterinary surgery. The main options of treatment include claw trimming along with various methods to speed up healing. At the same time, the problem of finding new agents to improve tissue regeneration remains. Mesenchymal stem cells (MSCs) cells may be considered as such a remedy. To evaluate the ability of bovine MSCs from adipose tissue (AT-MSCs) when used after claw trimming to heal the ulcers of digital caudation in the heel area (*Ulcus Pulvinus Digitalis*) or postoperative wounds after excision of interdigital hyperplasia (tyloma) in dairy cows. The experimental and comparison groups included 5 cows with ulcers and 5 with tylomas each. All the animals underwent claw trimming with primary surgical treatment including the tyloma excision. Then, cows in experimental group were once injected with a cell transplant into the skin area of the fornix of the interdigital cleft. The cows in comparison group received a single intramuscular injection of antibiotic and topical treatment of lesions with a spray. The therapy outcomes were assessed in dynamics of the wound healing and general condition. AT-MSCs at a dose of 5×10^6 cells in 2 ml in the case of ulcers and 10^7 cells in 4 ml of saline solution in the case of tylomas shortens the wound healing period by $(7.0 \pm 2.1, P < .05)$ days as compared to the treatment with antibiotic and topical spray. The mesenchymal stem cells-based therapy may be used for wound healing in cow hooves.

Keywords: Adipose tissue, claws and hooves, dairy cow, mesenchymal stem cells, wound healing.

INTRODUCTION

Claw (hoof) disorders are a serious problem for modern dairy cattle breeding. They are associated with the vast majority of cases of lameness in cows, increase the cost of production, lead to a decrease in dairy productivity, culling of animals, high herd rotation, a qualitative and quantitative decrease in reproduction (Dolecheck *et al.*, 2019; Kofler, 2017). A predisposition to claw disorders in cows is determined by a branched network of a large number of blood vessels in the distal part of limbs, chronic venous insufficiency associated with the restricted movement of animals in large livestock farms, and the main trigger is the traumatization of hooves on hard floor coverings. To date, the therapy of cows with limb diseases should be carried out comprehensively, taking into account species and individual characteristics, the reactivity

of the animal to injury, anatomical features and structure of the damaged tissue, the nature of the damaged tissue, the duration of tissue injury during operations, localization of injury, blood circulation disorders in damaged tissues and organs, and others. The most versatile and widely used treatment of claw disorders is claw (hoof) trimming. Further therapy is mostly empirical, varying from farm to farm and is not effective enough as evidenced by the consistently high percentage of animal culling. The currently used topical therapy may require repeated time-consuming treatments of pathological foci. In general, the lack of effectiveness of the tools applied may be due to the complex etiology of claw lesions combined with the selectivity and narrow targeting of the drugs applied.

Currently, the use of mesenchymal stem cells (MSCs) is considered a promising approach to the treatment of a number

Kostyuk, N., A. Prytychenka, I. Volotovskiy, I. Vasilevich, S. Pinchuk, V. Rukal, R. Borisik and A. Karabassova. 2025. The Use of Adipose-Derived Mesenchymal Stem Cells in the Treatment of Claw Lesions in Cows. Journal of Global Innovations in Agricultural Sciences 13: xxxxx.

[Received 2 Sept 2024; Accepted 4 Nov 2024; Published (online) 8 Nov 2024]



Attribution 4.0 International (CC BY 4.0)

of diseases in cattle (Hill *et al.*, 2019). Firstly, MSCs are known for their anti-inflammatory properties, which are critical in reducing the prolonged inflammatory response associated with chronic wounds such as digital cushion ulcers and postoperative wounds from tyloma excision. By modulating the immune response, MSCs decrease the levels of pro-inflammatory cytokines, which helps prevent further tissue damage and promotes a shift towards tissue repair (Jervis *et al.*, 2019). Secondly, MSCs stimulate angiogenesis—the formation of new blood vessels—by secreting growth factors like vascular endothelial growth factor (VEGF). This is essential for delivering oxygen and nutrients to the damaged tissues, which accelerates the healing process, especially in poorly vascularized areas like the hooves (Caplan, 2017). Furthermore, the immunomodulatory abilities of MSCs, combined with their capacity to differentiate into fibroblast-like cells, contribute to efficient epithelialization and wound closure. This is particularly important for hoof lesions that tend to heal by secondary intention, where the stimulation of both fibroblasts and keratinocytes can significantly reduce healing times (Ankrum *et al.*, 2014). Mesenchymal stem cells (MSCs) are considered as potential agents to accelerate wound healing and restore normal tissue architecture. These cells act at all stages of wound healing, with the immunomodulatory properties of MSCs and the production of growth factors playing an important role (Nourian Dehkordi *et al.*, 2019). At present, there is quite a large amount of data accumulated, indicating a high regenerative ability of MSCs when applied for wound healing in human. However, there are no publications on the use of MSCs for the treatment of claw lesions in cattle. Since hoof wounds in cows heal by secondary tension, stimulation of angiogenesis under the action of MSCs may promote formation of granulation tissue and further epidermization. The idea of this work was to apply MSCs after functional claw trimming and primary surgical treatment. At the present time, cell therapy with the use of MSCs is becoming increasingly popular in veterinary medicine. Most often, MSCs are used to cure companion animals and in sport horse breeding, while therapy's potential in animal farming is not used extensively. There are reports of successful treatment of mastitis in cows (Cahuascano *et al.*, 2019; Hill *et al.*, 2019; Peralta *et al.*, 2020; Sharma *et al.*, 2017) of the use of MSCs in bone and joint injuries (Grayson *et al.*, 2015) in reproduction of cattle, in particular, when transferring somatic cell nuclei (Abouhamzeh *et al.*, 2015; Oliveira *et al.*, 2020; Raoufi *et al.*, 2011) and obtaining transgenic animals (Sharma *et al.*, 2017; Yang *et al.*, 2011) for the treatment of diabetes of cattle (Clark, 2003). This study has shown that MSCs can be used to heal wounds in hooves. Currently, the problem of treatment of ulcers of the digital caushion (*Ulcus Pulvinus Digitalis*) in the heel area and interdigital hyperplasia (tylomas of the fornix of interdigital cleft) in cattle refers to the most relevant aspects of veterinary

surgery in our country. Depending on the method and system of keeping, feeding and degree of hoof care the share of these pathologies amounts from 5% to 20% and more in the total number of the registered diseases of the limbs (Rukal, 2014). When using different current treatment options it takes a long time (up to 35 days) to restore the function of damaged tissues depending on pathology severity. Shortening the recovery period may greatly increase the profitability of production. In this work, we aimed to evaluate the ability of allogeneic bovine adipose tissue derived-MSCs (AT-MSCs) applied after claw trimming to heal ulcers *Ulcus Pulvinus Digitalis* in the heel area (chronic non-healing wounds) and postoperative wounds after removal of tylomas of the fornix of interdigital cleft in dairy cows. However, the application of MSCs to treat hoof and claw lesions in dairy cows, such as digital cushion ulcers and postoperative wounds after tyloma excision, has been largely unexplored. To date, there is a lack of published data specifically investigating the role of MSCs in the treatment of claw disorders in cattle, despite the high prevalence of these conditions and the significant economic impact they have on dairy farming. This study aims to bridge that gap by evaluating the therapeutic potential of adipose-derived MSCs (AT-MSCs) in healing claw lesions. Unlike previous studies focused on reproductive or mastitis treatments, our research pioneers the use of MSCs for addressing hoof injuries, exploring the ability of these cells to accelerate wound healing, reduce lameness, and potentially reduce culling rates associated with claw diseases.

MATERIALS AND METHODS

Adipose tissue extraction: Adipose tissue (AT) sampling was performed at a local meat processing plant from the slaughter bullocks (aged 16-18 months) no later than 30 minutes after the slaughter. The material for MSCs isolation was subcutaneous adipose tissue from the base of the tail. Approximately, 5-10 cm³ of adipose tissue was cut out with a sterile scalpel after the cauterization of an incision area. The tissue samples were immersed for 30 seconds in 70% ethanol for surface disinfection without damaging the central part of the sample (Freshney, 2005). After that, the adipose tissue pieces were placed in phosphate buffered saline – PBS (Biowest, France) with the addition of 100 IU/ml penicillin, 80 IU /ml streptomycin and 2.4 IU /ml amphotericin B (Biowest, France) and transported to the laboratory for cell isolation and culture.

AT-MSCs isolation and culture: MSCs were isolated and cultured under sterile conditions according to GMP requirements. AT-samples were digested in 0.1% collagenase I solution (Life Technologies) for 60 minutes at 37 °C. Collagenase I activity was neutralized with fetal bovine serum – FBS (HyClone, UK) to a final concentration of 5%. The disrupted tissue was thereafter centrifuged at 370 × g for 10



minutes. The sediment consisting of the stromal-vascular fraction was resuspended in DMEM (Sigma) supplemented with 10% FBS, 2 mM L-glutamine (Sigma), 100 UI/ml penicillin, 80 UI/ml streptomycin and 2.4 UI/ml amphotericin B (expansion medium) and plated in the amount of 10^5 cells/cm². The cells were cultivated in the disposable plastic Petri dishes of 35 mm in diameter or in culture flasks for adhesion cultures (Sarstedt, Germany) in the CO₂ incubator at 37 °C under a humid atmosphere with 5% CO₂. The cells not adherent to the plastic were removed by means of a change of culture medium. The expansion medium was changed for the first time after 24 hours, and then every 72 hours. Upon reaching 80 – 90 % confluence of cell monolayer AT-MSCs were passaged by removal with 0.25% trypsin in the 0.02% EDTA (Biowest, France) supplemented with 100 UI/ml penicillin, 80 UI/ml streptomycin and 2.4 UI/ml amphotericin B. For this, the monolayer was washed PBS and treated with the trypsin/EDTA solution for 1-3 minutes at 37°C. Trypsin was neutralized with the DMEM medium supplemented with 3% FBS. Then the cell suspension was centrifuged at $370 \times g$ for 10 minutes, the supernatant was discarded, and the cell pellet was diluted with the expansion medium. The cells were sown for the next passage in the amount of 5×10^3 cells/cm². After 3 to 4 passages cells were characterized and cryopreserved.

Cell morphology and viability: The morphology of the cells in the process of their cultivation was evaluated by phase-contrast microscopy (inverted microscope "Olympus SKX41" (Japan). The boundaries between the cells obtained should be clearly distinguished, and the cells themselves should have a fibroblast-like morphology. Cell viability was determined by staining with 0.04% trypan blue solution (Bio-Rad, UK) with the count of colored (dead) and unpainted (viable) cells in the Goryaev's chamber.

Flow cytometry analysis: The immunophenotype of AT-MSCs cultures was determined using FITC-labeled monoclonal antibodies to the surface markers of MSCs: CD44 (Thermo Fisher Scientific, UK) and CD90 (Novus Bio-Techne Ltd, UK) and the marker of hematopoietic cells CD45 (Thermo Fisher Scientific, UK) on a flow cytometer "FACSCanto II" (Becton Dickinson, USA). For this, 10^5 cells were resuspended in 100 µl PBS with 1% FBS, then an antibody was added in dilution according to the manufacturer's instructions and the cells were incubated with each of the antibodies to the CD44, CD90 and CD45 surface antigens for 60 minutes in the dark with careful stirring every 10 minutes. Next, the cells were centrifuged at $370 \times g$ and resuspended in 300 µl PBS for measurement on a flow cytometer. As a background control, cells without the addition of antibodies were used.

Sterility control: AT-MSCs sterility (no contamination with fungi and bacteria) was controlled using macroscopic and microscopic studies. To detect contamination with aerobic and anaerobic bacteria, the suspension of cultured cells was

incubated in the thioglycolic medium for at least 14 days at a temperature of +35 °C. To reveal fungal contamination, a suspension of cells in the Sabouraud agar was placed into the thermostat at a temperature of +25 °C and incubated for at least 14 days.

Cryopreservation of cells: The accumulated AT-MSCs biomass was cryopreserved in a cryoprotective medium containing 45 % DMEM, 45% FBS, and 10% DMSO (Sigma). The cells were frozen using a programmable cryofreezer "Cryologic CL8800i" (Australia). According to the program, the samples were kept at a temperature of 5.5 °C for 10 minutes, then cooled to a temperature of -120 °C at a rate of 1°C per min.

Description of a cell transplant: To prepare the transplant, cryopreserved cells were thawed and propagated by passaging *in vitro*. The transplant for injection was a suspension of AT-MSCs in saline solution. The cells in the suspension were rounded in shape, and when seeded in an expansion medium during the formation of a monolayer, they acquired a spindle-shaped (fibroblast-like) morphology after 48 hours. The cell cultures of the transplants were tested for compliance with the norms of viability (more than 90% of viable cells), immunophenotype (CD90 and CD44-more than 90%, CD45 – less than 3%) and sterility. The shelf life of the cell transplant from the date of issue was no more than 12 hours at a temperature of +4 °C to +10 °C and no more than 4 hours at a temperature of +10 °C to +37 °C.

Planimetric method for determining the area of the wound surface: The wound area was determined by the contact way according to the method of Kundin (1989). Wound length and width were measured so that these values were the largest and located along perpendicular axes. The wound area (S-wound) was calculated according to the formula: $S\text{-wound} = L \times W \times 0.785$, where L – length of the wound, W – width of the wound.

Veterinary clinical trials of AT-MSCs transplant: Veterinary clinical trials of the AT-MSCs transplant were conducted in dairy farm. The animals were kept in the same conditions of feeding and care, in a clean room with a dry floor and soft bedding. Initially, the animals were selected on the signs associated with claw lesions, such as primarily lameness, etc. Then cows were undergoing a thorough mechanical cleaning of the distal parts of the limbs and animals with ulcers of the digital caushion (*Ulcus Pulvinus Digitalis*) in the heel area and interdigital hyperplasia (tylomas of the fornix of interdigital cleft) were selected. In all animals with ulcers the following was observed: sick animals lay down more; stood up with difficulty; they had lameness; local temperature was elevated; the ulcer surface was moist, dirty gray in color, its edges were thickened, bleeding easily. The average area of the ulcer lesion was $(13.84 \pm 3.94 \text{ cm}^2)$. In animals with tylomas there was a well-defined clinical picture: tyloma reached the size of a walnut, growing in the interdigital cleft in the palmar (plantar) direction.



The experimental and comparison groups of 10 cows, five with ulcers and five with tylomas in each, were formed according to the principle of conditional analogies. All animals underwent functional claw trimming, surgical excision of tyloma, removal of necrotic tissues and overgrown pathological granulations. After primary surgical treatment, the wounds were treated with 3% hydrogen peroxide solution. Wound lesions of comparison group cows were also cauterized with powder (potassium permanganate, brilliant green, streptocide in equal weight ratio). The clinical criteria for the readiness of the affected claw for further therapy were the absence of fibrin plaque, purulent exudate, and a decrease in inflammatory changes in the tissue. Further, the animals of the experimental group were injected with an AT-MSCs into the skin area of the fornix of the interdigital cleft as close as possible to the pathological focus. All the cows with ulcers were injected with AT-MSCs transplant at a dose of 5×10^6 cells in 2 ml of saline solution. All the animals with the post-operative wounds after tyloma excision received a cell transplant at a dose of 10^7 cells in 4 ml of physiological solution as an injection. The administration of AT-MSCs was performed once with the use of conduction anesthesia and no later than 4 hours after preparation of a cell transplant. After the introduction of the AT-MSCs suspension, an aseptic dressing was applied to the treated hoof, which protected the wound and the transplanted cell culture from infection. After the antiseptic wound treatment described above, the cows of the comparison group were once administered intramuscularly in the neck area with antibiotic ceftiofur (6.6 mg per 1 kg of animal weight) and an antiseptic dressing was applied. About an average of 9 days later, a single or more treatment of the affected area with the "Intra Hoof-fit Spray" (Intracare BV, Netherlands) was performed. The effectiveness of treatment was evaluated in dynamics based on the clinical picture of the general condition and the regenerative process. The clinically evaluated signs were the respiratory rate and pulse rate, the degree of lameness, the presence of soreness, the area of the wound defect, the condition of the surrounding tissues (edema, hyperemia), the nature of the exudate released, the degree of granulation tissue development, and the timing of wound epithelization.

Statistical analysis: All the data obtained were presented as an arithmetic mean with a mean square deviation (mean \pm SD). To assess the reliability of the differences between the groups, the Student's criterion was used. $P < 0.05$ was considered statistically significant.

RESULTS

Obtaining AT-MSCs culture: The method of AT-MSCs obtaining consisted of the isolation of the stromal-vascular fraction and selection of these cells during subsequent cultivation due to their ability to adhere to the plastic. The cells were cultured for 30-35 days with a change of expansion

medium and passaging as described in Materials and Methods. The study of the morphology of cultured cells from the adipose tissue of cattle showed that during the cultivation period up to 10 days, the cells adhered to the cultured plastic had both a spindle-shaped and rounded or irregular shape (Fig. 1, 1a). At first, about on the 5th day, elongated cells appeared in the culture, some of them had a triangular or polygonal shape, a size of more than 40 microns, larger nuclei and were located at a large distance from each other. Approximately, on the 10th day of the culture growth, a homogeneous cytoplasm and the nuclei with a nucleolus were clearly visible in the cells. The size of these cells varied from 20 to 40 microns, they divided and began to form colonies. For periods of more than 15 days, spindle-shaped cells predominated in the culture (Fig. 1, 1b).

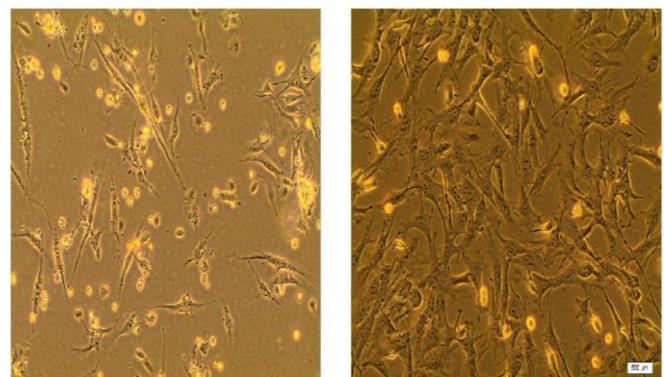


Figure 1. Cell morphology in culture during the isolation of MSCs from bovine adipose tissue. a, 10th day of cultivation, magnification 100 \times , b, 17th day of cultivation, magnification 400 \times , scale bar = 500 μ m. MSCs, mesenchymal stem cells.

Approximately, on the 20th day of cultivation, a monolayer of cells with a confluence of 80% had a tendency to form. After 2-fold passaging, the AT-MSC culture was represented mainly by a homogeneous population of spindle-shaped fibroblast-like cells (Fig. 2).

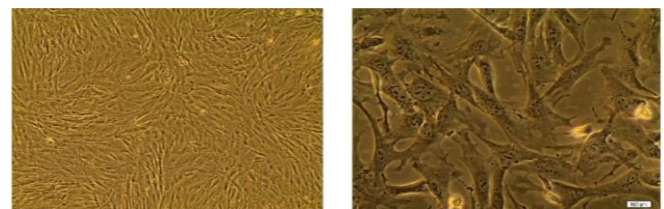


Figure 2. Monolayer formation in the second passage of MSCs culture obtained from bovine adipose tissue. a, magnification 100 \times . b, magnification 400 \times . Scale bar = 500 μ m. MSCs, mesenchymal stem cells.

The analysis of the immunophenotype of the 2-nd passage cell culture demonstrated a high content of cells expressing such



markers as CD44 and CD90 (90-95%), and a low percentage of cells expressing CD45 (0.8-1.2%), which meets the criteria of high purity of AT-MSCs (Fig. 3).

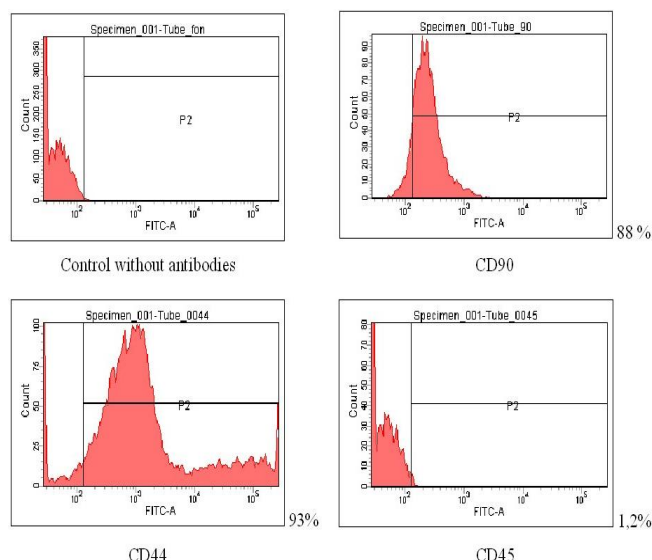


Figure 3. The result of a typical experiment on cell immunophenotyping using labeled antibodies to mesenchymal and hematopoietic surface markers. CD90, CD44 are markers specific to MSCs; CD 45 is a marker of hematopoietic cells that characterizes the homogeneity of the MSCs preparation. MSCs, mesenchymal stem cells.

As a result, MSCs of the second passage isolated from subcutaneous fat of the base of the tail of bullocks had a stable immunophenotype, high proliferative activity and viability of more than 90%. With further cultivation up to fourth passage, these characteristics of MSCs were not change.

AT-MSCs transplant trials in dairy cows with claw lesions:

The test design of trials is described in the materials and methods. In the animals selected for clinical trials, either ulcers of the digital caushion in the heel area with a pronounced inflammatory reaction of the surrounding tissues were observed (edematous, painful with the presence of small foci of necrosis) or the tylomas of the fornix of interdigital cleft, which were surgically excised. Before the therapy, all sick cows demonstrated the suppressed general condition, the decreased food excitability and reactions to the surrounding environment. The body temperature was within the normal. Respiratory and pulse rates were increased. There was also a pronounced support-type lameness. Prior to cell therapy, the suspension of AT-MSCs of cattle was checked for sterility as described in the methods. The cell suspension was considered sterile if no microbial growth was observed in any of the seeded tubes or Petri dishes. If growth was detected in at least one of the tubes or Petri dishes, regardless of the nature of the microflora, the suspension was considered non-sterile.

The treatment regimen and clinical signs used to evaluate its effectiveness are described in the materials and methods.

The cows of the experimental group already on about day 5 showed an improvement in their general condition. After removing the protective dressing and examining the wound, a

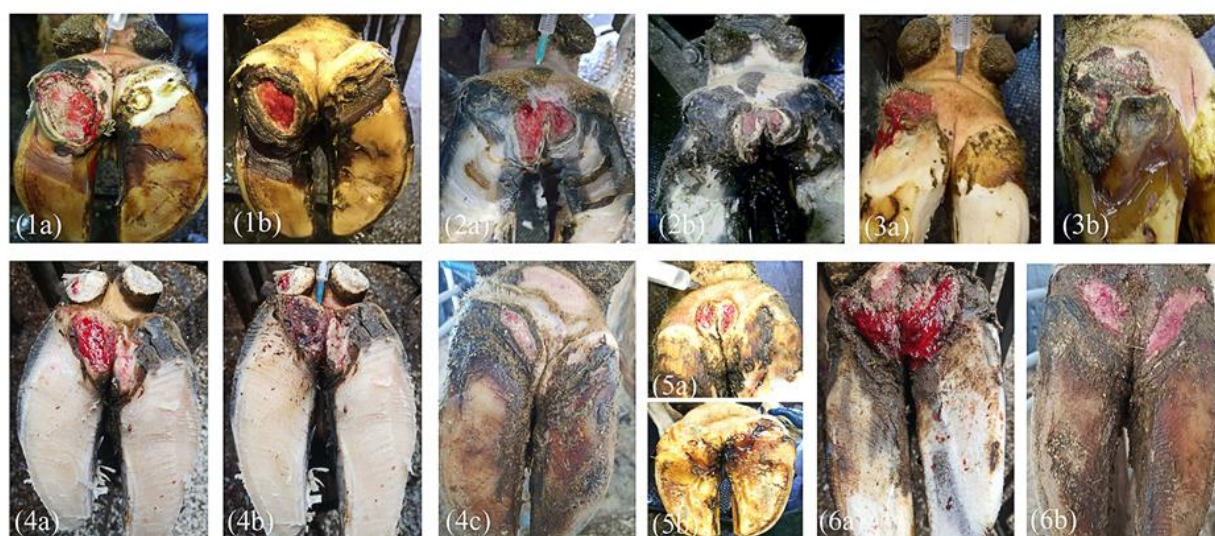

Figure 4. Visual appearance of hooves of cows with the ulcers of the digital caushion in the heel area. 1-5, Experimental group; 6, Comparison group. 1a – 6a and 4b, Ulcers after claw trimming and primary surgical treatment. 1b – 3b, Healing of the wounds on the 7th day after the onset of therapy. 4c, 5b, 6b, Healing of thewounds on the 14th day after the onset of therapy. 1b, 2b, 5b, Scab formation. 4b, Change of wound appearance sometime after treatment with 3% hydrogen peroxide.



decrease in the tissue swelling and the pain attenuation were observed, but the animals were relying on the injured leg falteringly. Local changes were characterized by the presence of granulation tissue. Treatment of the affected area with help spray in cows of the experimental group was not performed. After about 12 days, the size of the wound defect was significantly reduced, the entire wound was filled with granulation tissue, and the growth of the epidermal rim was observed at the edges of the wound. There was no swelling or hyperemia of the tissue in the wound area. The animals confidently leaned on the affected limb and there was a barely noticeable lameness when moving. The protective dressing was not applied further. On about day 17, in the group of cows with the use of AT-MSCs, the entire surface of the wound was filled with healthy pink granulation tissue during its visual inspection. There was an active growth of the epidermal rim, and scar tissue formed on the site of the ulcer and tyloma. When walking, the animals confidently stepped on the affected limb and there was no lameness. Complete clinical recovery occurred on average (19.5 ± 1.5) days after the start of the use of stem cells.

In the cows of the comparison group on about 9 days after the start of treatment, the overall condition was satisfactory and the antiseptic dressing was removed. However, lameness was noted during movement, the animals carefully leaned on the affected limb, pain and swelling persisted. The surface of the wound was slightly dried, the area of the wound was covered with a brown crust. Further treatment of the affected area was carried out with a topical aerosol spray. Local changes were characterized by a decrease in the swelling of the tissues, the preservation of soreness and the formation of normal granulation tissue was noted. On about day 25, the wound surface was filled with fine-grained granulation tissue. Recovery of animals of this group occurred on day (26.5 ± 1.5). Thus, it was shown that that the use of AT-MSCs of cattle at a dose of 5×10^6 cells in 2 ml or 10^7 cells in 4 ml of saline solution shortens the healing period of a purulent-necrotic focus by (7.0 ± 2.1) days as compared to the animals treated with antibiotic and help spray. Examples of cell therapy results are shown in Figs. 4 and 5. It should be noted that healing of wounds could take place with the formation of scabs (Figs. 1b, 2b, 5b).

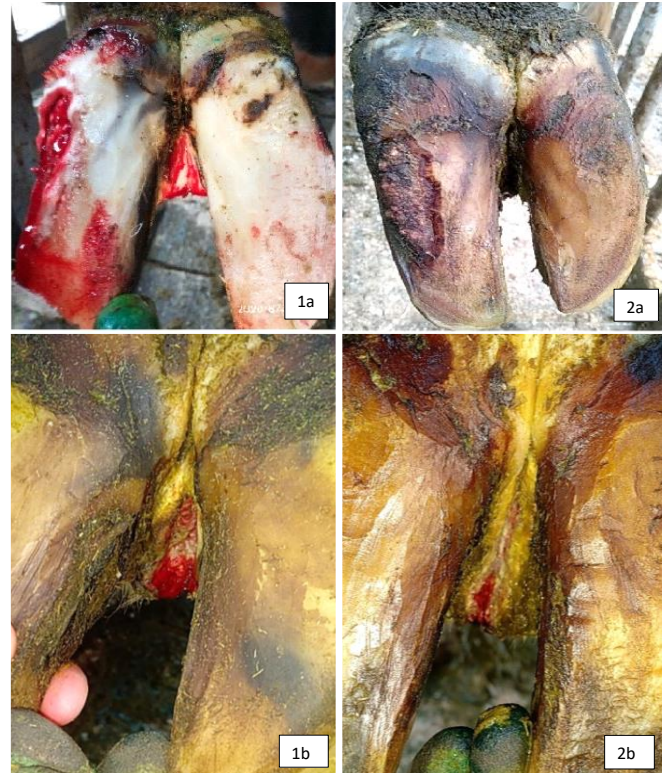

Figure 5. Visual appearance of hooves of cows with the interdigital hyperplasia. 1, Experimental group; 2, Comparison group. 1a and 2a, Clinical cases of tyloma. 1b and 2b, Wounds after claw trimming and surgical excision of tylomas.

The rate of surface healing was also estimated by the percentage of the area of wound healing (epithelization) to total wound area, Table 1.

The total healing time for cows treated with AT-MSCs was 19.5 ± 1.5 days, while for cows in the comparison group, the healing time was significantly longer at 26.5 ± 1.5 days ($p < 0.001$). This 7-day reduction in healing time (mean difference of 7.0 ± 2.1 days) is statistically significant, supporting the hypothesis that AT-MSCs shorten the wound recovery period more effectively than traditional treatments.

Table 1. Relative increase of wound healing area in cows with claw lesions (mean \pm SD, $P < 0.05$).

Period from the beginning of therapy, day	Name of the group of 10 cows	S1/S2, %		p-value
		For the entire period	Per day of the period	
7	E	34.37 ± 2.63	4.91 ± 0.38	$p < 0.01$
	C	17.64 ± 1.35	2.52 ± 0.19	
14	E	65.66 ± 5.48	4.69 ± 0.39	$p < 0.05$
	C	47.04 ± 4.08	3.36 ± 0.29	
21	E	91.56 ± 7.64	4.36 ± 0.36	$p < 0.05$
	C	63.21 ± 4.52	3.01 ± 0.22	



DISCUSSION

Traditional treatments for claw lesions in dairy cows, such as claw trimming, antibiotics, and topical antiseptic sprays, while widely used, have notable limitations. These approaches often require repeated treatments, are labor-intensive, and may have limited efficacy, particularly in cases of chronic, non-healing wounds like digital cushion ulcers. Furthermore, the overuse of antibiotics is becoming a significant concern in veterinary medicine, contributing to the rise of antibiotic-resistant bacteria and posing a risk of antibiotic residues in milk and meat products (Dolecheck *et al.*, 2019). In contrast, MSC therapy offers several potential advantages over these conventional methods, which has been proved by the obtained results. Mesenchymal stem cells (MSCs) are known to have a therapeutic effect on disorders in the target organ, regardless of the source of the tissue from which they are isolated (Cortes *et al.*, 2013). Moreover, AT-MSCs obtained from different anatomical sites of the same donor have a similar morphology and phenotype (Choudhery *et al.*, 2015). According to published data, bone marrow (Bosnakovski *et al.*, 2005; Cortes *et al.*, 2013; Dueñas *et al.*, 2014; Lee *et al.*, 2015), adipose tissue (Oliveira *et al.*, 2020; Sampaio *et al.*, 2015), umbilical cord (Raoufi *et al.*, 2011; Xiong *et al.*, 2014) placenta and fetal fluid (Peng *et al.*, 2017), uterine endometrium can be used as sources for bovine MSCs (de Moraes *et al.*, 2016; Donofrio *et al.*, 2008; Lara *et al.*, 2017). Currently, bone marrow and adipose tissue are the main sources of MSCs in medicine, including veterinary (Chung *et al.*, 2012). Mesenchymal stem cells from adipose tissue (AT-MSCs) have such advantages over MSCs from bone marrow as faster development *in vitro*, easier isolation, and higher density of stromal cells (Chung *et al.*, 2012; Hill *et al.*, 2019; Neupane *et al.*, 2008). When choosing bovine adipose tissue as a source of mesenchymal stem cells, the authors of this work were guided by the above considerations, as well as the results of studies on the treatment of leg ulcers in human (Baranov *et al.*, 2013). This work showed that subcutaneous adipose tissue from the base of the bovine tail is a suitable source for obtaining cell cultures with fibroblast-like morphology and immunophenotype corresponding to the MSC authenticity criteria. These cultures had a stable immunophenotype, high proliferative activity and viability. The tests on dairy cows showed that local injection of the transplant of the obtained cells reduced the healing time of claw wounds in cows by (7.0 ± 2.1) days as compared to intramuscular injection of antibiotic followed by application of a topical spray. To obtain the MSCs of cattle, the adipose tissue of slaughter bullocks was used. In contrast to human and small animals, when it is possible to cut out the material in sterile operating rooms, the sampling of adipose tissue of cattle was carried out in the slaughterhouse of a meat processing plant, that is, in conditions of an increased risk of contamination of tissue samples with microorganisms.

However, the generally accepted simple measures to ensure sterility such as sterilization of instruments, cauterization of the incision site, placing the biopsies of tissue in 70% ethanol for 30 seconds, adding antibiotics to the media for samples were enough to obtain a biomaterial that meets the requirements of sterility in the preparation of MSCs. According to our data, incubation of adipose tissue samples in 70% ethanol for 30 seconds have no effect on the quality of AT-MSCs on the parameter of cell viability. Positive markers of mesenchymal stem cells CD90 and CD45 were used as positive criteria for characterizing the purity of the obtained AT-MSCs of cattle, and CD44 was used as a negative marker of hematopoietic cells (Dueñas *et al.*, 2014; Gao *et al.*, 2014; Lee *et al.*, 2015; Peng *et al.*, 2017; Xiong *et al.*, 2014). The resulting cellular material was laid down for cryopreservation. To obtain a cell transplant, thawed and *in vitro* passaged cells were used, which did not differ in their characteristics from fresh ones, which is consistent with the data of other authors (de Moraes *et al.*, 2016). The delivery of the received preparations to the farm to treat animals was carried out as quickly as possible (within 4 hours) in order to avoid changes in the viability of AT-MSCs and to prevent their contamination (Webster *et al.*, 2012). The introduction of stem cells was performed as early as possible after claw trimming and primary surgical treatment, since it is known that MSCs cell therapy is most effective at the acute inflammatory stage during the fibroblastic (proliferative) phase of tissue healing (Schnabel *et al.*, 2013). A very important point of this study was the choice of cell dose for the treatment. The dose of MSCs was chosen based on studies on the treatment of leg ulcers in humans (Baranov *et al.*, 2013), data on the treatment of mastitis in cows (Peralta *et al.*, 2020), as well as data from this study on the effectiveness of the dose used depending on the claw pathology. The choice of the skin area of fornix of interdigital cleft as a site for MSCs injection was based on the localization of pathological foci, as well as on a large number of blood vessels and good innervation in it, which allowed the injected cells to spread rapidly in the wound area. Calculations of the cost-effectiveness of wound healing using MSCs were not performed at this stage of the study. However, the authors would like to note the factors that allow to talk about its feasibility. It can be assumed that MSCs therapy probably provides more guarantees of healing, being a more universal tool, acting less dependent on the etiological factors of the disease. If this proves to be true in the course of additional studies, the cell therapy may be applied in particularly severe clinical cases. In addition, stem cells may be used to treat the most valuable animals, including individual animals. It should also be taken into account that traditional topical treatment of hoof lesions often involves more than one labor-intensive treatment compared to a single stem cell injection. In general, MSCs therapy can be economically feasible if a dedicated



center with sufficient workload and the use of sufficiently inexpensive reagents is established.

Conclusion: Stem cell therapy, as shown in this study, may be applied to treat cows with digital heel ulcers (*Ulcus pulvinus digitalis*) and interdigital hyperplasia after claw trimming and primary surgical treatment, including tyloma excision. The use of mesenchymal stem cells may be a more successful alternative to antibiotic therapy, which can lead to resistant strains of microorganisms infecting both animals and humans, as well as to antibiotic contamination of meat and dairy products. While the sample size of 10 cows per group was sufficient to demonstrate statistically significant differences between the treatment and comparison groups, a larger sample size could further strengthen the statistical power and confidence in these findings. Future research should explore the long-term effects of MSC therapy on hoof lesion recurrence and investigate the potential for scaling up MSC production for broader use in veterinary practices.

Funding: Separate project of fundamental and applied research of the NAS of Belarus.

Conflict of interest: The authors declare no conflicts of interest related to this report.

Author contributions: All authors contributed equally to the study.

Availability of data and material: Data supporting the findings of this study are available from the corresponding author upon reasonable request.

Acknowledgment: We would like to thank reviewers and the editor of the Journal of Global Innovations in Agricultural Sciences for their invaluable assistance and support throughout this study.

Code Availability: Not applicable. No custom code or software was developed as part of this study.

Consent to participate: Not applicable. The study did not involve human participants, so no consent to participate was required.

Consent for publication: All authors have read and approved the final manuscript for publication.

SDG's addressed: This study contributes to the United Nations' Sustainable Development Goal (SDG) 12: Responsible Consumption and Production, by exploring alternative treatments to reduce the use of antibiotics in livestock, thereby supporting responsible and sustainable agricultural practices.

REFERENCES

- Abouhamzeh, B., M. Salehi, A. Hosseini, A.R. Masteri-Farahani, F. Fadaei, M.H. Heidari, M. Nourozian, M. Soleimani, M. Khorashadizadeh, M. Mossahebi-Mohammadi and A. Mansouri. 2015. DNA Methylation and histone acetylation patterns in cultured bovine adipose tissue-derived stem cells (BADSCs). *Cell Journal* 16:466-475.
- Ankrum, J.A., J.F. Ong and J.M. Karp. 2014. Mesenchymal stem cells: Immune evasive, not immune privileged. *Nature Biotechnology* 32:252-260.
- Baranov, E.V., S.I. Tretjak, I.B. Vasilevich, E.S. Lobanok and I.D. Volotovskiy. 2013. Klinicheskiye vozmozhnosti primeneniya autogennykh mul'tipotentnykh mezenkhimnykh stromal'nykh kletok zhirovoy tkani pri lechenii patsiyentov s troficheskimi yazvami nizhnikh konechnostey [The clinical application of autologous mesenchymal stem cells isolated from fat tissue for the treatment of patients with trophic ulcers of lower extremities]. *Geny i kletki* 8:79-84.
- Bosnakovski, D., M. Mizuno, G. Kim, S. Takagi, M. Okumura and T. Fujinaga. 2005. Isolation and multilineage differentiation of bovine bone marrow mesenchymal stem cells. *Cell and Tissue Research* 319:243-253.
- Cahuascano, B., J. Bahamonde, O. Huaman, M. Jervis, J. Cortez, J. Palomino, A. Escobar, P. Retamal, C.G. Torres and O.A. Peralta. 2019. Bovine fetal mesenchymal stem cells exert antiproliferative effect against mastitis causing pathogen *Staphylococcus aureus*. *Veterinary Research* 50:25.
- Caplan, A.I. 2017. Mesenchymal stem cells: Time to change the name! *Stem Cells Translational Medicine* 6:1445-1451.
- Choudhery, M.S., M. Badowski, A. Muise, J. Pierce and D.T. Harris. 2015. Subcutaneous adipose tissue-derived stem cell utility is independent of anatomical harvest site. *BioResearch Open Access* 4:131-145.
- Chung, D.J., K. Hayashi, C.A. Toupadakis, A.W. Clare and E. Yellowley. 2012. Osteogenic proliferation and differentiation of canine bone marrow and adipose tissue derived mesenchymal stromal cells and the influence of hypoxia. *Research in Veterinary Science* 92:66-75.
- Clark, Z. 2003. Diabetes mellitus in a 6-month-old Charolais heifer calf. *The Canadian Veterinary Journal* 44:921-922.
- Cortes, Y., M. Ojeda, D. Araya, F. Dueñas, M.S. Fernández and O.A. Peralta. 2013. Isolation and multilineage differentiation of bone marrow mesenchymal stem cells from abattoir-derived bovine fetuses. *BMC Veterinary Research* 9:133.
- de Moraes, C.N., L. Maia, M.C. Dias, C.P. Dell'Aqua, L.S. da Mota, A. Chapwanya, F.D. Landim-Alvarenga and E. Oba. 2016. Bovine endometrial cells: A source of



- mesenchymal stem/progenitor cells. *Cell Biology International* 40:1332-1339.
- Dolecheck, K.A., M.W. Overton, T.B. Mark and J.M. Bewley. 2019. Estimating the value of infectious or noninfectious foot disorder prevention strategies within dairy farms, as influenced by foot disorder incidence rates and prevention effectiveness. *Journal of Dairy Science* 102:731-741.
- Donofrio, G., V. Franceschi, A. Capocefalo, S. Cavirani and I.M. Sheldon. 2008. Bovine endometrial stromal cells display osteogenic properties. *Reproductive Biology and Endocrinology* 6:65.
- Dueñas, F., V. Becerra, Y. Cortes, S. Vidal, L. Sáenz, J. Palomino, M. De Los Reyes and O.A. Peralta. 2014. Hepatogenic and neurogenic differentiation of bone marrow mesenchymal stem cells from abattoir-derived bovine fetuses. *BMC Veterinary Research* 10:154.
- Freshney, R.I. 2005. Chapter 12: Primary culture, In: R.I. Freshney (Ed.), *Culture of Animal Cells: A Manual of Basic Technique*, 5th ed. John Wiley & Sons, New York pp. 175-197.
- Gao, Y., Z. Zhu, Y. Zhao, J. Hua, Y. Ma and W. Guan. 2014. Multilineage potential research of bovine amniotic fluid mesenchymal stem cells. *International Journal of Molecular Sciences* 15:3698-3710.
- Grayson, W.L., B.A. Bunnell, E. Martin, T. Frazier, B.P. Hung and J.M. Gimble. 2015. Stromal cells and stem cells in clinical bone regeneration. *Nature Reviews Endocrinology* 11:140-150.
- Hill, A.B.T., F.F. Bressan, B.D. Murphy and J.M. Garcia. 2019. Applications of mesenchymal stem cell technology in bovine species. *Stem Cell Research & Therapy* 10:44.
- Jervis, M., O. Huaman, B. Cahuascanco, J. Bahamonde, J. Cortez, J.I. Arias, C.G. Torres and O.A. Peralta. 2019. Comparative analysis of in vitro proliferative, migratory and pro-angiogenic potentials of bovine fetal mesenchymal stem cells derived from bone marrow and adipose tissue. *Veterinary Research Communications* 43:165-178.
- Kofler, J. 2017. Pathogenesis and treatment of toe lesions in cattle including "nonhealing" toe lesions. *Veterinary Clinics of North America: Food Animal Practice* 33:301-328.
- Kundin, J.I. 1989. A new way to size up a wound. *The American Journal of Nursing* 89:206-207.
- Lara, E., N. Rivera, D. Rojas, L.L. Rodríguez-Alvarez and F.O. Castro. 2017. Characterization of mesenchymal stem cells in bovine endometrium during follicular phase of oestrous cycle. *Reproduction in Domestic Animals* 52:707-714.
- Lee, S.H., S.H. Cha, C.L. Kim, H.S. Lillehoj, J.Y. Song and K.W. Lee. 2015. Enhanced adipogenic differentiation of bovine bone marrow-derived mesenchymal stem cells. *Journal of Applied Animal Research* 43:15-21.
- Neupane, M., C.C. Chang, M. Kiupel and V. Yuzbasiyan-Gurkan. 2008. Isolation and characterization of canine adipose-derived mesenchymal stem cells. *Tissue Engineering Part A* 14:1007-1015.
- Nourian Dehkordi, A., F. Mirahmadi Babaheydari, M. Chehelgerdi and S. Raeisi Dehkordi. 2019. Skin tissue engineering: wound healing based on stem-cell-based therapeutic strategies. *Stem Cell Research & Therapy* 10:111.
- Oliveira, B.M., A. Pinto, A. Correia, P.G. Ferreira, M. Vilanova and L. Teixeira. 2020. Characterization of myeloid cellular populations in mesenteric and subcutaneous adipose tissue of Holstein-Friesian Cows. *Scientific Reports* 10:1771.
- Peng, S.Y., C.W. Chou, Y.H. Kuo, P.C. Shen and S.S. Shaw. 2017. Potential differentiation of islet-like cells from pregnant cow-derived placental stem cells. *Taiwanese Journal of Obstetrics and Gynecology* 56:306-311.
- Peralta, O.A., C. Carrasco, C. Vieytes, M.J. Tamayo, I. Muñoz, S. Sepulveda, T. Tadich, M. Duchens, P. Melendez, A. Mella and C.G. Torres. 2020. Safety and efficacy of a mesenchymal stem cell intramammary therapy in dairy cows with experimentally induced *Staphylococcus aureus* clinical mastitis. *Scientific Reports* 10:2843.
- Raoufi, M.F., P. Tajik, M.M. Dehghan, F. Eini and A. Barin. 2011. Isolation and differentiation of mesenchymal stem cells from bovine umbilical cord blood. *Reproduction in Domestic Animals* 46:95-99.
- Rukal, V. 2014. Rasprostraneniye i nozologiya khirurgicheskikh bolezney u krupnogo rogatogo skota [Distribution and nosology of surgical disease in cattle]. *Farm Animals* 2:44-48.
- Sampaio, R.V., M.R. Chiaratti, D.C.N. Santos, F.F. Bressan, J.R. Sangalli, A.L. Sá, T.V. Silva, N.N. Costa, M.S. Cordeiro, S.S. Santos, C.E. Ambrosio, P.R. Adona, F.V. Meirelles, M.S. Miranda and O.M. Ohashi. 2015. Generation of bovine (*Bos indicus*) and buffalo (*Bubalus bubalis*) adipose tissue derived stem cells: Isolation, characterization, and multipotentiality. *Genetics and Molecular Research* 14:53-62.
- Schnabel, L.V., L.A. Fortier, C.W. McIlwraith and K.M. Nobert. 2013. Therapeutic use of stem cells in horses: which type, how, and when? *The Veterinary Journal* 197:570-577.
- Sharma, N., D.L. Huynh, S.W. Kim, M. Ghosh, S.S. Sodhi, A.K. Singh, N.E. Kim, S.J. Lee, K. Hussain, S.J. Oh and D.K. Jeong. 2017. A PiggyBac mediated approach for lactoferricin gene transfer in bovine mammary epithelial stem cells for management of bovine mastitis. *Oncotarget* 8:104272-104285.
- Webster, R.A., S.P. Blaber, B.R. Herbert, M.R. Wilkins and G. Vesey. 2012. The role of mesenchymal stem cells in



- veterinary therapeutics—a review. New Zealand Veterinary Journal 60:265-272.
- Xiong, H., C. Bai, S. Wu, Y. Gao, T. Lu, Q. Hu, W. Guan and W. Ma. 2014. Biological characterization of mesenchymal stem cells from bovine umbilical cord. Animal Cells and Systems 18:59-67.
- Yang, B., J. Wang, B. Tang, Y. Liu, C. Guo, P. Yang, T. Yu, R. Li, J. Zhao, L. Zhang, Y. Dai and N. Li. 2011. Characterization of bioactive recombinant human lysozyme expressed in milk of cloned transgenic cattle. PLoS One 6:e17593.

