EXTRACTION OF VERTEBRAE AND RIBS FROM CT IMAGES

B. Zalesky, S. Ablameyko, A. Nedzved, P. Lukashevich
United Institute of Informatics Problems NAS of Belarus, Minsk

The algorithm to extract vertebrae and ribs from 2D CT images of human body is proposed. It provides reliable determining of rounded part of a vertebra, extraction of this bone together with ribs (if they touch the vertebra), and then detaching ribs from segmented image. The algorithm does not require any preliminary learning and can be applied to CT images of medical DICOM and usual graphic formats.

Introduction

There is no need to explain important role of medical imaging in current human life. One of actual problems of modern medical imaging is task of extraction of vertebrae from MR and CT images. Evidently, results of this computer sciences problem are useful for medical specialists, especially for those who study or treat spinal deceases. Besides, extraction of vertebrae and ribs are used in order to segment other internal human organs, such as kidney, the liver, lungs etc.

Now there are many approaches to the problem. Among them are model-based, discrete optimization, neural network, active contours, morphologic algorithms or their combinations [1-4] with or without of use a prior information etc. As other image extraction and segmentation algorithms they are divided into classes of manual, semi-automatic and automatic ones. Now manual and semi-automatic algorithms prevail in real applications. Though, automatic model based methods found their use in practical medical imaging, as well.

We developed a new fully automatic algorithm to extract vertebrae and ribs from CT images in medical DICOM and usual graphic formats. The algorithm does not need preliminary learning and instead of comparatively complicated 3D model of the vertebrae it works with simple 2D heuristic, which, however, allows reliable determining rounded part of this bone (fig. 1, a,b).

Tests of the algorithm showed its applicability for extraction of the spine, however, in some rare cases it separates vertebrae and ribs not quite accurately. So, for instance, for database consisting more than 800 slice CT images it found correctly 98% of interior elliptic parts of vertebrae and separated correctly spine and ribs in 95% cases.

1. Extraction Algorithm

The algorithm contains following main steps: image preprocessing that includes moving off artificial noisy clusters; finding body section; reliable detection of round part of the vertebra; accurate extraction of this bone, which image can break up into several parts and be touched by ribs; discrimination between the spine and ribs, image postprocessing .

Image preprocessing is performed by a version of the region growing algorithm leaving only the largest connected component of the CT image, which always is the body section, and removing all other artifacts and noisy clusters. After, the region of interest (ROI) is found as the rectangular bounding box of the body section, and another smaller ROI, which certainly contains the vertebra, is computed.

CT images are usually stored in the DICOM format that makes possible use of Hounsfield units. It is known (and approved by practice) the bones in DICOM images have the highest Hounsfield brightness (1000 - 1200) in comparison with other parts of human body (excluding cases when patient took special contrast agent). This fact together with a simple prior knowledge on elliptic form of the interior part of the vertebra allows accurate its determining. Then, top boundary of the vertebrae is determined (Fig.1c). In case of standard gray-scale representation of CT images equalization of histogram is fulfilled first and then the highest values of equalized histogram is exploited to find the elliptic part of the vertebra.

Further outlining of the vertebra boundary is started from the lowest pixel of this bone (fig. 1, *d),* since 2D slice CT image of this one piece bone can contain different number of separate

parts. The algorithm outlines bottom part of the vertebra together with ribs if they look touching the bone. In some DICOM images Hounsfield brightness of pixels of ribs touching the vertebra is greater than 1000. In this case ribs and the vertebra look as one object. In other cases they look separated ab origin. The algorithm recognizes the case we have and separates touching ribs. Finally image post-processing is done to close the contour.

Below the description of the algorithm of automatic unsupervised extraction of vertebrae and ribs from CT images in the DICOM format is presented. The main difference of the version this algorithm from the version that works with 256 color grayscale CT images consists in use of Hounsfield units without histogram equalization whereas this procedure is fulfilled for standard gray scale images. Note that all pictures in figures of the paper was done after conversion resulting DICOM images in the standard 256 color grayscale format and equalization since direct their visualization leads to very low-contrast ones. First three images in Fig1a,b,c were equalized by the ezDicom package but all other ones were processed by equalizer written by the authors.

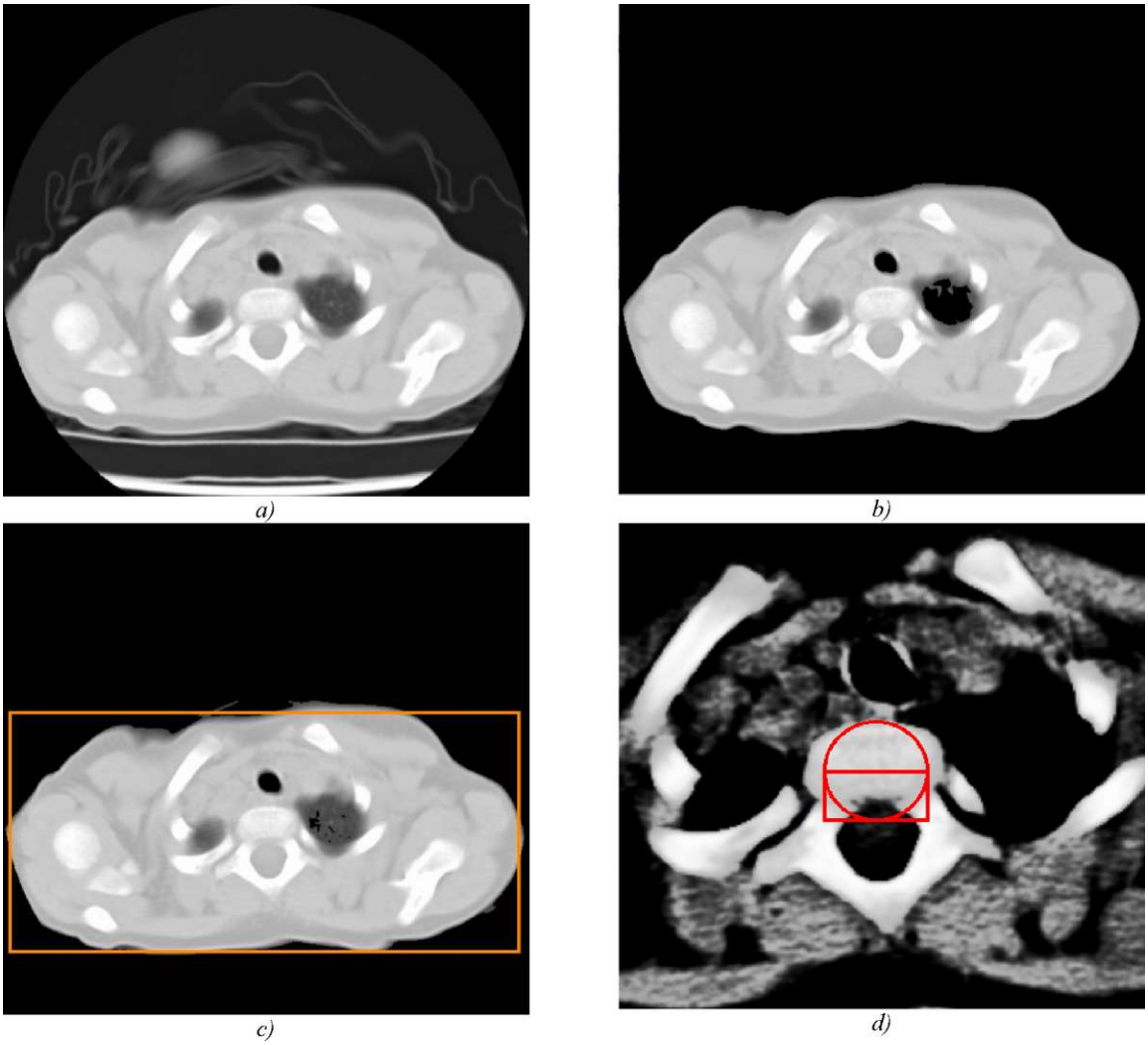

Fig.1. Images: *a)* the original, equalized by the ezDicom; *b)* after preprocessing by the region growing algorithm; *c)* ROI; *d)* after matching the kernel

Before detailed description of the algorithm let us formulate its main stages:

Step 1. Image preprocessing.

Step 2. Finding the elliptic interior part of the vertebra.

Step 3. Outlining the elliptic part of the vertebra.

Step 4. Extraction of lower part of the vertebra.

Step 5. Recognition and discrimination of ribs if they touch the vertebra.

Step 6. Postprocessing of vertebra image.

As it can be seen in fig. 1, *a* original CT images often contain objects that does not belong a human body and noisy clusters. The region growing algorithm is used to remove them and leave only body section (fig. 1, *b).* Then the rectangular box of the body image forming the ROI is determined. The procedure of building the smaller bounding box certainly containing the vertebra image finishes the preprocessing.

At Step2 the kernel of the form shown in picture Fig.1d, which is union of the circle and the rectangle, is applied to find the internal elliptic part of the vertebra. Despite of simple form of the kernel it finds the rounded part of the bone very reliably. At step 3 the algorithm outlines this rounded part by means of the contouring algorithm (fig. 2, *a).*

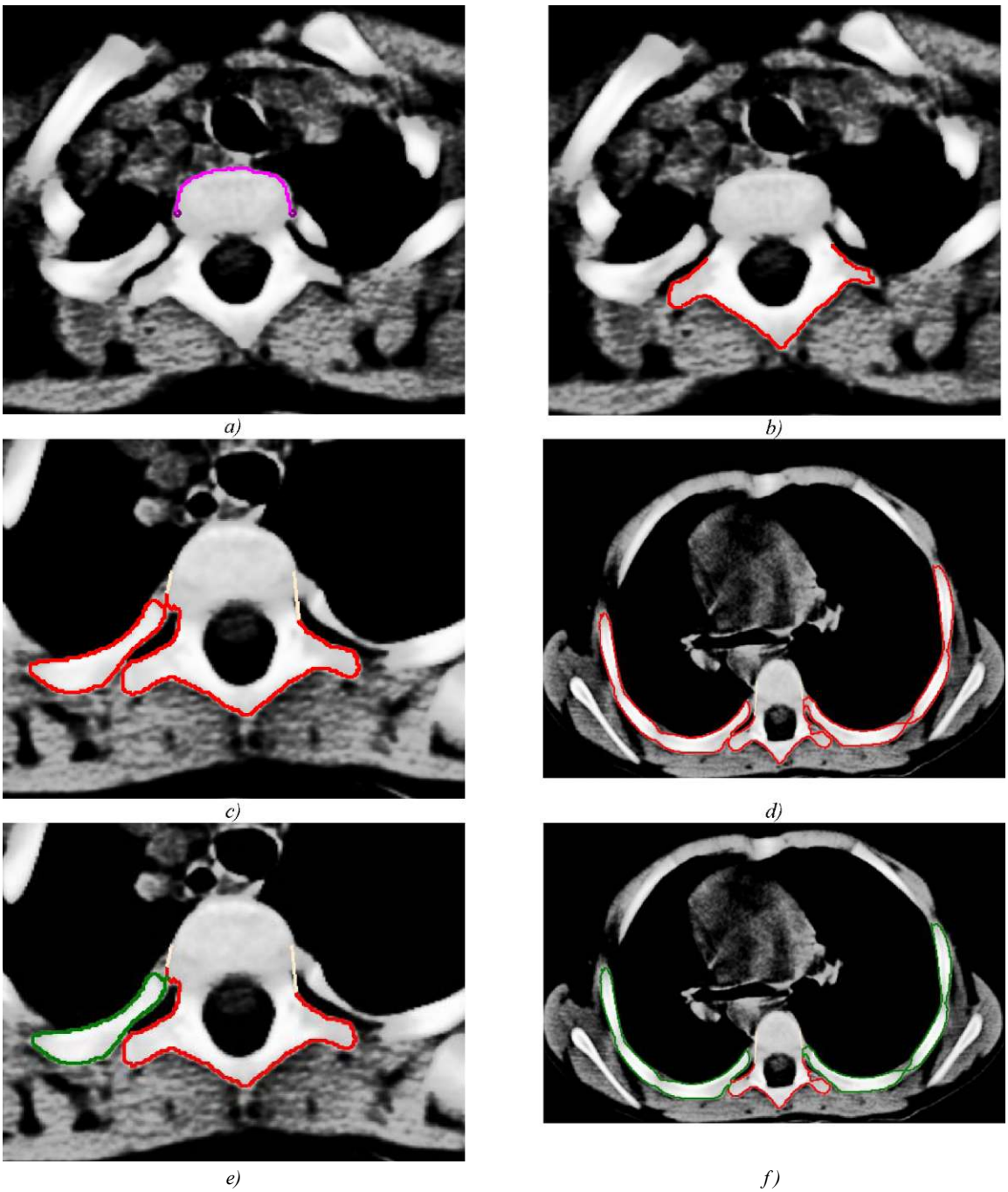

Fig. 2. Pictures: *a)* with the contour, outlining interior elliptic part of the vertebra; *b)* after outlining the bottom part of the vertebra without touching ribs; *c),d)* after outlining the bottom part of the vertebra with touching ribs; *e)f)* ribs separated by the algorithm are drown in green

Step 4 starts with founding lowest pixel of the vertebra. Then contouring algorithm find in turn left and right bottom parts of the vertebra, possibly, with left and right ribs, if their pixels touching the vertebra have Hounsfield brightness above the minimum value corresponding density of bones. At this step we take in account cases when bottom part of the vertebra image can look as several disjoint bones. Results of selection of the vertebra without touching ribs and with them are depicted in fig. 2, *b,c,d.*

To discriminate touching ribs several techniques can be used. For instance, in [5-6] authors use several template images of vertebrae and match them in accordance with an actual CT image of the vertebra. Of course, use information from other already segmented 2D slice CT images lightens the task o discrimination the vertebra and ribs, as well. However, another approach that functions without any prior graphic information also gives good results. The ribs are discriminated from the vertebra by finding and cut large loops in the determined lower contour.

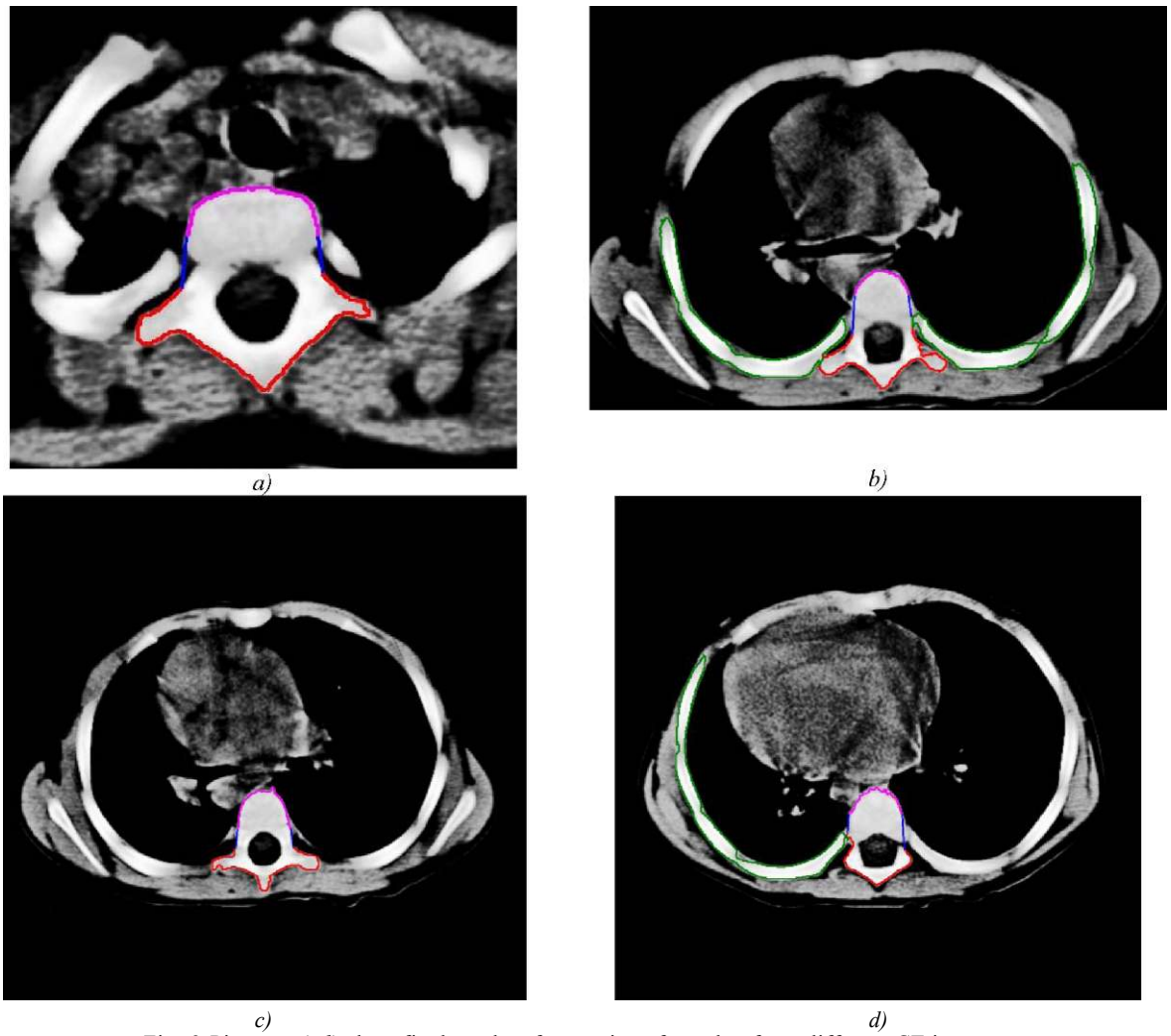

Fig. 3 Pictures *a)-d)* show final results of extraction of vertebra from different CT images

Postprocessing at Step 6 consists in closing of top and bottom parts of the segmented contour. Series of segmented vertebrae are depicted in fig. 3.

2. Experiments

The dataset of consisting of 847 plane CT scans (stored in the DICOM format files) of 15 patients has been processed to test the algorithm.

Originally the DICOM format represents grayscale images by 16bit signed brightness. How-

ever, grayscale CT images of human bodies have intensities *Ix,y,* belonging to interval $0 < I_{x,y} <$ 1200^1400 which is called the Hounsfield scale. Before execution of main steps the algorithm converted pictures to conform to the Hounsfield scale.

After that the algorithm recognized correctly 98% rounded parts of vertebrae and extracted correctly 95% of images of this bone separated from ribs.

The algorithm worked incorrectly in cases when: 1) there was not the vertebra in 2D CT image, at all; 2) in 2D CT image presented an internal organ with Hounsfield brightness higher that brightness of the vertebra (it sometimes happen if patient took special contrast agent); 3) the last bottom vertebra has very special form.

We hope to improve the algorithm to indicate correctly images without the vertebra, since in these cases the statistic, responsible for matching the kernel, usually has greater values than in case of presence of this bone.

From our point of view, the second and the third cases can also be processed more accurately that will increase preciseness of the algorithm.

Conclusion

A new unsupervised algorithm to segment vertebrae in 2D CT images has been presented. It allows reliable finding this bone and its automatic extraction. The algorithm does not use prior information on the spine shape. The results of tests showed possibility of automatic extraction of vertebra from CT images. In order to be applicable to practical extraction the algorithm needs following feasible improvements in order to: process correctly images, which do not contain the vertebra; process in special way CT images of patients that took contrast agents; test shapes of outlines contours.

The research has been supported by the ISTC B-1489 grant.

References

1. Serlie I.W.O., Vos F.M., Truyen R., Post, F.H. van Vliet, L.J. Classifying CT Image Data Into Material Fractions by a Scale and Rotation Invariant Edge Model // IP, vol. 16, n. 12, 2007. - P. 2891-2904.

2. Wang L.I., Greenspan M., Ellis R.E. Validation of bone segmentation and improved 3-D registration using contour coherency in CT data // MedImg, vol. 25, n. 3, 2006. - P. 324-334.

3. Seise M., McKenna S.J., Ricketts I.W., Wigderowitz C.A. Learning Active Shape Models for Bifurcating Contours // MedImg, vol. 26, n. 5, 2007. - P. 666-677.

4. Yao W., Abolmaesumi P., Greenspan M., Ellis R.E. An Estimation/Correction Algorithm for Detecting Bone Edges in CT Images // MedImg, vol. 24, n. 8, 2005. - P. 997-1010.

5. Jackowski M. and Goshtasby A., A computer-aided design system for segmentation of volumetric images // in Handbook of Biomedical Image Analysis, vol. 3: Registration Models, J. S. Suri, D. L. Wilson, and S. Laxminarayan. - Kluwer Academic, New York, 2005. - P. 251-272.

6. Zagorchev L., Goshtasby A., Satter M., Bernstein T. Segmentation and Registration of Spinal MR and CT Images // http://www.cs.wright.edu/~agoshtas/wkni_spine.html.